

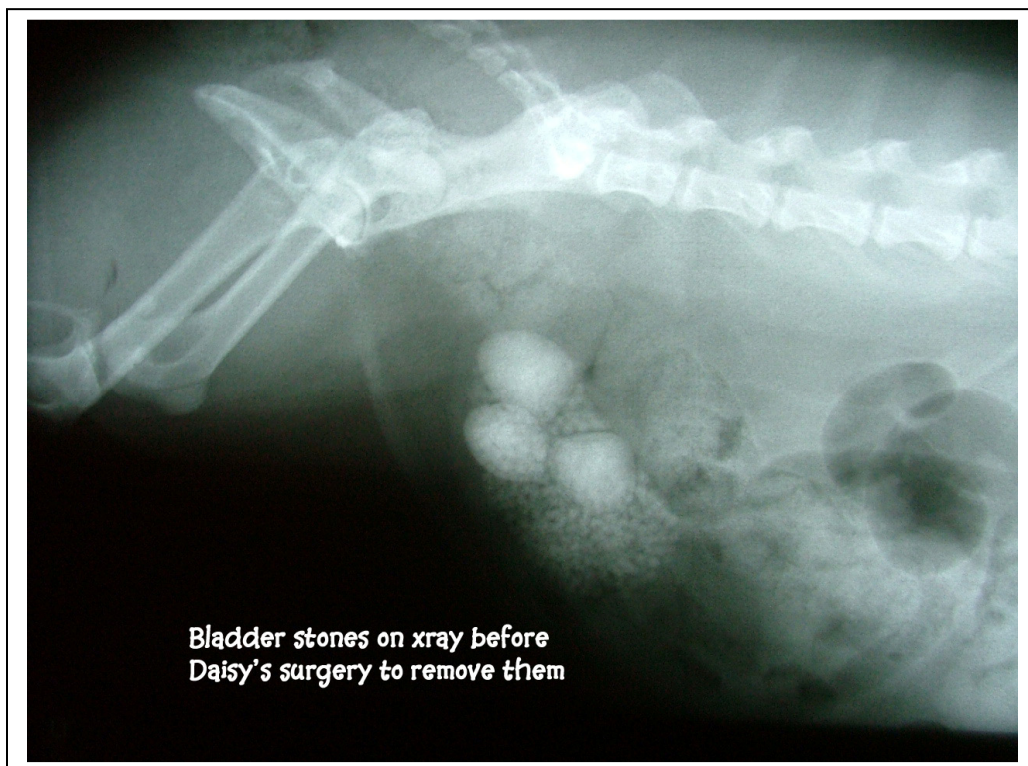
# THE CASE OF MAKING ONE'S OWN STONES



Daisy is almost 10 years old, a spayed female Shitzu. She has been having trouble urinating frequently, with blood, and straining at the same time.

Upon examination, the doctor could feel what seemed to be bladder stones.

An abdominal xray confirmed his suspicions:



After surgery, in which the bladder was cut open to remove all the stones, laser therapy was performed both on the bladder incision and also on the skin incision to enhance healing and lower pain.

The following stones were then photographed, before being divided to give to the owner and to send to the lab to find out their composition. Once we find out what they are made of, we can then place Daisy on a prescription food to help prevent further occurrence.

A urine culture was taken and it confirmed that the antibiotic chosen should work to get rid of further bladder infection left from the stones.

